

Island of misfit tortoises: waif gopher tortoise health assessment following translocation

Rebecca K. McKee^{1,2,*}, Kurt A. Buhlmann¹, Clinton T. Moore³, Matthew C. Allender⁴, Nicole I. Stacy⁵ and Tracey D. Tuberville¹

¹Savannah River Ecology Laboratory, University of Georgia, PO Drawer E, Aiken, SC 29802, USA

²Warnell School of Forestry and Natural Resources, Georgia Cooperative Fish and Wildlife Research Unit, University of Georgia, 180 E Green Street, Athens, GA 30602, USA

³U.S. Geological Survey, Georgia Cooperative Fish and Wildlife Research Unit, 180 E Green Street, Athens, GA, 30602, USA

⁴Wildlife Epidemiology Lab, College of Veterinary Medicine, University of Illinois, 2001 S. Lincoln Ave., Urbana, IL 61802, USA

⁵Department of Comparative, Diagnostic, and Population Medicine, College of Veterinary Medicine, University of Florida, 2015 SW 16th Ave, Gainesville, FL 32610, USA

*Corresponding author: Department of Wildlife Ecology and Conservation, University of Florida, Mailing: P.O. Box 110430, 110 Newins-Ziegler Hall, Gainesville, FL 32611, USA. Tel: 828-226-0926. Email: remckee2014@gmail.com

Translocation, the intentional movement of animals from one location to another, is a common management practice for the gopher tortoise (*Gopherus polyphemus*). Although the inadvertent spread of pathogens is a concern with any translocation effort, waif tortoises—individuals that have been collected illegally, injured and rehabilitated or have unknown origins—are generally excluded from translocation efforts due to heightened concerns of introducing pathogens and subsequent disease to naïve populations. However, repurposing these long-lived animals for species recovery is desirable when feasible, and introducing waif tortoises may bolster small populations facing extirpation. The objective of this study was to assess the health of waif tortoises experimentally released at an isolated preserve in Aiken County, SC, USA. Our assessments included visual examination, screening for 14 pathogens using conventional or quantitative polymerase chain reaction (qPCR) and haematological evaluation. Of the 143 individuals assessed in 2017 and 2018, most individuals (76%; $n = 109$ of 143) had no overt clinical evidence of disease and, when observed, clinical findings were mild. In both years, we detected two known tortoise pathogens, *Mycoplasma agassizii* and *Mycoplasma testudineum*, at a prevalence of 10.2–13.9% and 0.0–0.8%, respectively. Additionally, we found emydid *Mycoplasma*, a bacterium commonly found in box turtles (*Terrapene* spp.), in a single tortoise that showed no clinical evidence of infection. The presence of nasal discharge was an important, but imperfect, predictor of *Mycoplasma* spp. infection in translocated tortoises. Hemogram data were comparable with wild populations. Our study is the first comprehensive effort to assess pathogen prevalence and hemogram data of waif gopher tortoises following translocation. Although caution is warranted and pathogen screening necessary, waif tortoises may be an important resource for establishing or augmenting isolated populations when potential health risks can be managed.

Key words: upper respiratory tract disease, translocation, stress, mycoplasma, *Gopherus*, captivity

Editor: Steven Cooke

Received 15 November 2021; Revised 23 June 2022; Editorial Decision 25 June 2022; Accepted 5 July 2022

Cite as: McKee RK, Buhlmann KA, Moore CT, Allender MC, Stacy NI, Tuberville TD (2022) Island of misfit tortoises: waif gopher tortoise health assessment following translocation. *Conserv Physiol* 10(1): coac051; doi:10.1093/conphys/coac051.

Introduction

Translocation is the intentional movement of animals from one location to another. The practice has become an important tool for proactively managing imperilled wildlife species (Johnson *et al.*, 2010; Biggins *et al.*, 2011; Kraus *et al.*, 2017). Despite the potential for success and its common use (Fischer and Lindenmayer, 2000; Germano and Bishop, 2009), translocation also carries many potential risks to wildlife health (Deem *et al.*, 2001; Kock *et al.*, 2010). In the United States, several pathogens and parasites have spread through the translocation of wild turkeys (*Meleagris gallopavo*; Castle and Christensen, 1990), raccoons (*Procyon lotor*; Schaffer *et al.*, 1981) and white-tailed deer (*Odocoileus virginianus*; Davidson *et al.*, 1996; Cohen *et al.*, 2018). Additionally, translocation can induce physiological stress (Teixeira *et al.*, 2007). In addition to the stress associated with capture and transport, translocated individuals may experience behavioural changes following release, such as increased movement and diet shifts, that result in more prolonged physiological stress (Dickens *et al.*, 2010). Increased stress can cause mortality (Hartup *et al.*, 1999) or indirectly affect health through immune system suppression and consequent downstream effects (Teixeira *et al.*, 2007).

Because herpetofauna, including chelonians, have declined in recent decades (Gibbons *et al.*, 2000; Stuart *et al.*, 2004; Stanford *et al.*, 2020), conservationists are increasingly tasked with balancing the potential benefits of management interventions such as translocation with potential adverse effects (Jacobson, 1994; Walker *et al.*, 2008; Aiello *et al.*, 2014). Numerous translocation efforts have been successful for herpetofauna species (Fitzgerald *et al.*, 2015; Jarvie *et al.*, 2016; Bell and Herbert, 2017; Kraus *et al.*, 2017). However, emerging infectious diseases pose challenges for both the conservation of *in situ* populations (Daszak *et al.*, 2000; Tompkins *et al.*, 2015) as well as translocation programs (Pessier, 2008; Walker *et al.*, 2008). The gopher tortoise (*Gopherus polyphemus*) is a long-lived species endemic to the southeastern United States and is among the most commonly translocated reptile species (Tuberville *et al.*, 2008). The species has been federally listed as threatened in the western portion of its range since 1987 (United States Fish and Wildlife Service [USFWS], 1987) and has more recently become a candidate for federal listing throughout the remainder of its range (USFWS, 2011). Historically, gopher tortoises have been translocated as mitigation for construction activities (Florida Fish and Wildlife Conservation Commission [FFWCC], 2006; FFWCC, 2012; Sullivan *et al.*, 2015). As development continues to fragment tortoise habitat, there is growing interest in using translocation as a tool to manage population viability (Gopher Tortoise Council, 2014).

Although habitat loss is the primary driver of declines for gopher tortoises (Smith *et al.*, 2006), disease is also considered a threat (Jacobson, 1994; McLaughlin, 1997). Upper respi-

ratory tract disease (URTD) caused by pathogenic bacteria in the genus *Mycoplasma* (with possible revision to genus *Mycoplasmopsis*; Gupta *et al.*, 2018), has historically been the focal disease of management concern (Jacobson *et al.*, 2014). Experimental trials confirmed *M. agassizii* as the etiologic agent of URTD for gopher tortoises (Brown *et al.*, 1999), and a second etiologic agent, *M. testudineum*, was later identified (Brown *et al.*, 2004). URTD has been a suspected factor in declines for both Mojave desert tortoises in California (*Gopherus agassizii*, Jacobson *et al.*, 1991b; Berry *et al.*, 2020) and gopher tortoises in Florida (Gates *et al.*, 2002; Seigel *et al.*, 2003). Infections with *Ranavirus* spp. in gopher tortoises have also been documented (Westhouse *et al.*, 1996; Johnson *et al.*, 2008; Cozad *et al.*, 2020b), and although the effects on tortoise health are poorly understood, infections are often lethal in other chelonians (De Voe *et al.*, 2004; Sim *et al.*, 2016). Recent work has also revealed infection with a novel *Anaplasma* sp. (i.e. *Candidatus Anaplasma testudinis*), which may contribute to anaemia in gopher tortoises (Crosby *et al.*, 2021). In addition to previously documented pathogens, there are ongoing efforts to identify novel pathogens that may impact tortoise health (Desiderio *et al.*, 2021).

There are risks associated with any translocation; however, waif tortoises—tortoises that have been collected illegally, injured and rehabilitated or have unknown origins (FFWCC, 2012)—are typically excluded from translocation efforts due to heightened concerns of introducing pathogens. In the case of the congeneric desert tortoise, released pets have been implicated in spreading pathogens, including the causative agents for URTD (Schumacher *et al.*, 1993; Jacobson, 1994; Johnson *et al.*, 2006; Berry *et al.*, 2015). Additionally, stress is an important concern with waif tortoises due to their history of captivity. Even short-term captivity can be stressful to wildlife (Gregory *et al.*, 1996), and prolonged captivity can alter behaviour, physiology or nutritional status (Mason, 2010; DeGregorio *et al.*, 2013, 2017), potentially making the transition back to the wild more stressful. However, as the species continues to decline (Smith *et al.*, 2006), waif animals could provide the needed individuals to bolster isolated wild populations. Additionally, an understanding of the suitability of formerly captive individuals for release will be important for the conservation of other long-lived reptiles that face similar challenges following their illegal collection and subsequent confiscation (Rosen and Smith, 2010; Mendiratta *et al.*, 2017).

In 1993, the discovery of a relict gopher tortoise population near Aiken, SC, USA, expanded the documented range for the species and inspired the creation of the Aiken Gopher Tortoise Heritage Preserve (AGTHP; Clark *et al.*, 2001). However, further surveys indicated that the population was too small to sustain itself without intervention. Due to the site's geographic isolation and lack of suitable donor animals from displaced wild tortoise populations, it was proposed to introduce waif tortoises in an effort to recover the relict population. Between 2006 and 2018, over 260 waif

tortoises from a variety of origins were released in the preserve (McKee *et al.*, 2021). No tortoises with clinical evidence of infection were released, but resource limitations prevented pathogen screening prior to release. Because waif tortoises present an ongoing management challenge and their potential contribution to recovery of wild populations is unknown, it is important to assess the health of released individuals. The objective of this study was to perform comprehensive health assessments of gopher tortoises released at the AGTHP, including visual examination, pathogen screening using traditional and quantitative PCR and haematological evaluation. Collectively, these data will serve as a monitoring baseline for comparison with future surveillance studies of this unique population, as well as inform a retrospective evaluation of the disease risks associated with translocations of waif gopher tortoises.

Methods

Study site

Located 30 km west of Aiken, SC, USA, the AGTHP was established by the South Carolina Department of Natural Resources (SCDNR) in 1993 to protect the northern-most population of gopher tortoises. Subsequent surveys in 1999 and 2001 determined that fewer than 15 tortoises resided on the property, which was isolated by over 50 km from the nearest native population (K. Buhlmann, Savannah River Ecology Laboratory, unpublished data, 2022). To prevent the population's extirpation, over 260 waif tortoises (including 203 juveniles, subadults and adults) were released between 2006 and 2018 to the now 656-ha property, and releases are ongoing as of 2022. Waif tortoises were obtained from state agencies, rehabilitation facilities, zoos, educational institutions and other partners. Prior to release, tortoises were visually inspected for signs of infection and the presence of ectoparasites, including the gopher tortoise tick (*Amblyomma tuberculatum*), and any ticks were removed. Groups of tortoises (\bar{x} = 13 adults) were soft-released into 1-ha circular pens for at least 10 months (following methods of Tuberville *et al.*, 2005) to promote site fidelity and development of social relationships (see McKee *et al.*, 2021 for details on release groups and tortoise origins).

Animal collection

This study was conducted in accordance with state permits (SCDNR Scientific Collection Permit Number #SC-04-2017, #SC-06-2018) and approved by University of Georgia IACUC protocols (AUP# A2017 05-022-Y1-A0). To locate tortoise burrows at AGTHP, we walked parallel transects spaced 15 m apart in all suitable habitat throughout the preserve during May–June 2017 and Feb–May 2018. We used a burrow camera to determine occupancy (Smith *et al.*, 2005). If a burrow was occupied, we placed a wire-live trap covered in shade cloth at the burrow opening (Aresco and Guyer, 1999). To prevent tortoises from overheating, traps were checked

multiple times daily (roughly every 4 h during 09:00–17:00). We also opportunistically captured any tortoise encountered outside of a burrow. Tortoises were transported in individual bins to the Savannah River Ecology Laboratory (located 38 km from AGTHP) where they were evaluated. Following their assessments, tortoises were kept overnight and returned to their point of capture within 24 h. During 2017 and 2018, wildlife agencies provided additional waif tortoises for release at AGTHP. Prior to their release, we processed these individuals similarly to captured tortoises.

We recorded the mass of tortoises to the nearest 2 g and measured to the nearest 1 mm the midline carapace length (MCL) from the nuchal scute to the supracaudal scute, the width at the widest point of the carapace, and the shell height at the highest point of the shell. We calculated tortoise body condition by dividing the mass (g) by the body shell volume (Loehr *et al.*, 2004; Daly *et al.*, 2018). To approximate shell volume, we used the formula for the half ellipsoid: shell volume (cm^3) = $(\pi \times \text{MCL} \times \text{width} \times \text{height})/6000$. Tortoises were classified as hatchlings, juveniles, subadults, adult males or adult females by their MCL and secondary sex characteristics (McKee *et al.*, 2021). We considered female tortoises <230 mm to be mature adults if they were determined as gravid via palpation.

Visual health assessments

Because many chelonian pathogens target the respiratory tract (Origi and Jacobson, 2000), we examined tortoises for evidence of upper respiratory infection. Individuals exhibiting nasal discharge, eroded nares, ocular discharge, ocular swelling or conjunctivitis were flagged as having clinical evidence of infection for known gopher tortoise pathogens, such as *Mycoplasma* spp. or *Ranavirus* spp. (Brown *et al.*, 1999; McLaughlin *et al.*, 2000; Brown *et al.*, 2004; Johnson *et al.*, 2008). Additionally, we assessed each tortoise's carapace, plastron, skin, cloaca, oral cavity, nares, eyes, tympanum and respiration and noted any abnormalities (see McKee, 2019 for full criteria). During examination, tortoises were also checked for ectoparasites.

Pathogen screening

We screened for 14 pathogens commonly associated with either wild or captive chelonian populations (Table 1). Due to the possibility that waif gopher tortoises had been exposed to conspecifics or other chelonian species while in captivity, our pathogen panel included some that have not specifically been documented in gopher tortoises but have been known to affect other species (Table 1). Separate oral and cloacal swabs were collected from each tortoise using sterile Copan Diagnostic Flocked Swabs® (Copan Diagnostics Inc, Murrieta, CA, USA). We also collected a nasal swab if a tortoise exhibited nasal discharge during assessment. Unlike previous research that used antibody tests to determine exposure (McLaughlin *et al.*, 2000; McGuire *et al.*, 2014), swabs were used for molecular testing to determine the presence of pathogen DNA.

Table 1: Pathogens tested in both oral and cloacal swabs collected from waif gopher tortoises at the AGTHP in Aiken County, SC, USA.

| Pathogen | Detection method | Documented in <i>G. polyphemus</i> | Literature documenting gopher tortoise infections | Source for qPCR primers |
|--|------------------|------------------------------------|---|---------------------------------------|
| <i>M. agassizii</i> | qPCR | Yes | Brown <i>et al.</i> , 1999 | Braun <i>et al.</i> , 2014 |
| <i>M. testudineum</i> | qPCR | Yes | Brown <i>et al.</i> , 2004 | Braun <i>et al.</i> , 2014 |
| Emydid <i>Mycoplasma</i> sp. ^a | qPCR | No | | In house |
| Frog Virus 3–Ranavirus | qPCR | Yes | Johnson <i>et al.</i> , 2008; Cozad <i>et al.</i> , 2020b | Pallister <i>et al.</i> , 2007 |
| Ambystoma tigrinum virus–Ranavirus | qPCR | No | | Pallister <i>et al.</i> , 2007 |
| <i>Bohle iridovirus</i> –Ranavirus | qPCR | No | | Pallister <i>et al.</i> , 2007 |
| Epizootic hemorrhagic necrosis virus–Ranavirus | qPCR | No | | Pallister <i>et al.</i> , 2007 |
| <i>Salmonella typhimurium</i> ^c | qPCR | Yes ^c | Lockhart <i>et al.</i> , 2008; Charles-Smith <i>et al.</i> , 2009 | Park <i>et al.</i> , 2008 |
| <i>Salmonella enteritidis</i> ^c | qPCR | Yes ^c | Lockhart <i>et al.</i> , 2008; Charles-Smith <i>et al.</i> , 2009 | Levin, 2009 |
| Testudinid herpesvirus 2 | qPCR | No | | Braun <i>et al.</i> , 2014 |
| Tortoise intranuclear coccidia | qPCR | No | | Alvarez <i>et al.</i> , 2013 |
| <i>Borrelia burdorferi</i> ^b | qPCR | No | | Golovchenko <i>et al.</i> , 2014 |
| <i>Anaplasma phagocytophilum</i> ^b | qPCR | No | | Vargas-Hernandez <i>et al.</i> , 2016 |
| Adenovirus ^b | PCR | No | | Wellehan <i>et al.</i> , 2004 |

Swabs were analysed at the Wildlife Epidemiology Laboratory at the University of Illinois where they were tested for 14 pathogens, including 10 pathogens tested in both 2017 and 2018 using conventional or quantitative polymerase chain reaction (PCR, qPCR respectively). Supporting citations are provided for pathogens that have been previously documented in gopher tortoises.

^aTested in 2018, but not in 2017.

^bTested in 2017, but not 2018.

^c*Salmonella* serotype not distinguished (Lockhart *et al.*, 2008; Charles-Smith *et al.*, 2009).

This screening method may result in an individual's status changing over sampling events (Aiello *et al.*, 2019; Burgess *et al.*, 2021). As such, if an individual captured in 2017 was recaptured in 2018, we collected oral swabs in both years and calculated prevalence annually. We analysed cloacal swabs in 2017 but did not detect pathogens (including individuals for which pathogens were detected in oral swabs), thus we did not analyse additional cloacal swabs for tortoises recaptured in 2018. However, we continued to collect and analyse cloacal swabs for tortoises first captured in 2018. We stored swabs at -80°C until analysis.

We extracted the DNA in oral and cloacal swab samples with a QIAamp Blood mini Kit (QIAGEN Inc., Redwood City, CA, USA), following the manufacturer protocol. Quantity ($\text{ng}/\mu\text{l}$) and quality (A260:A280 ratio) of DNA were evaluated using a Nanodrop spectrophotometer (Thermo Fisher Scientific Inc., Waltham, MA, USA). We performed qPCR in a multiplex format using published or in-house primer-probe assays to evaluate 13 of the pathogens—10 were assessed in both years, 2 were assessed in 2017 only and 1 was assessed in 2018 only (Table 1; Detection method = 'qPCR'). Initially, specific target amplification was performed on each sample with pooled pathogen Taqman assays and preamp mastermix (Thermo-Fisher, Waltham, MA, USA). Each reaction was performed under the following cycling program on an MJ Tetrad thermocycler: 95°C (10 min), 14 cycles of 95°C (15 sec) and 60°C (4 min). The qPCR assay was then performed in triplicate using $2.25\ \mu\text{l}$ of amplified DNA from the first reaction on a Fluidigm 96.96 Gene Expression IFC and amplified on the Fluidigm Biomark HD Real Time PCR thermocycler (Fluidigm, South San Francisco, CA, USA) using the following cycling protocol: 70°C (30 min), 25°C (10 min), 95°C (1 min), followed by 35 cycles at 96°C (5 sec) and 60°C (20 sec). Serial dilutions of positive controls for FV3-like *Ranavirus*, *M. agassizii* and *M. testudineum* were prepared from 10^7 to 10^1 copies per reaction. A non-template control was included on each plate. All reactions were then analysed using Fluidigm Real Time PCR analysis software (Fluidigm, South San Francisco, CA, USA). Following Fluidigm analysis, all positive samples were verified in a simplex reaction. Briefly, qPCR was performed in triplicate on a QuantStudio3 real time thermocycler. Samples were considered positive if all three replicates had a lower cycle threshold (C_t) value than the lowest detected standard dilution.

We used conventional PCR with a previously characterized two-step consensus assay for adenovirus detection for 2017 samples (Wellehan *et al.*, 2004; Table 1; Detection method = 'PCR'). Products were electrophoresed on a 1% agarose gel and compared with positive and negative controls and a 100 bp DNA ladder. The PCR products producing appropriately sized bands (approximately 320 base pairs) were treated with Exo-SAP-IT (USB Corporation, Cleveland, OH 44128, USA), sequenced in both directions (W.M. Keck Center for Comparative and Functional Genomics, University of Illinois at Urbana-Champaign, Urbana, IL) and compared

with known sequences in GenBank using BLASTN to confirm accurate detection.

Hemogram evaluation and hemoparasite quantification

Prior to collecting blood, the collection site was disinfected with alcohol wipes. For subadult and adult tortoises, we collected 0.5–1.5 ml of blood via the brachial vein using a 25-gauge heparinized needle. For juveniles, we used a 29.5-gauge needle to collect 0.3–0.6 ml of blood from the subcarapacial vein. Volume of blood collected did not exceed 0.5% of any tortoise's body weight. Blood was not collected from hatching tortoises. To minimize handling time for tortoises, we only collected blood from tortoises during their first capture, resulting in one blood sample per tortoise. Blood samples with overt lymph dilution (as evidenced by the sample coloration) were removed from hemogram analysis. For each tortoise, a capillary tube was filled with whole blood and centrifuged (LW Scientific, Zipocrit; $3636\times g$) to determine packed cell volume (PCV), a metric that quantifies the red blood cell (RBC) column relative to plasma. We used a refractometer (Reichert Technologies, Depew, NY, USA) to estimate total protein (TP; gL^{-1}). Following blood collection, we immediately prepared three to five blood smears that were then fixed with methanol and allowed to air dry prior to storage.

Blood films were stained using Wright-Giemsa (Harleco[®], EMD Millipore, Billerica, MA, USA) and screened for hemogregarines by counting the number of gametocytes in RBCs per 100 RBC. White blood cells (WBC), including WBC estimate (Weiss, 1984) and 200 WBC differential count, and blood cell morphology (WBC, RBC and thrombocytes) were assessed by blood film evaluation, an approach that has been used for many wildlife species (Davis *et al.*, 2008), including gopher tortoises (Goessling *et al.*, 2016; Cozad *et al.*, 2020a). Heterophils were categorized as either immature or mature (Stacy *et al.*, 2017; Stacy *et al.*, 2022). We calculated heterophil:lymphocyte ratios (H:L ratios) by dividing total heterophils (mature and immature) by total lymphocytes for each individual.

Modelling predictors of infection with URTD-associated pathogens

We used logistic regression models to identify individual attributes useful in predicting infection with *M. agassizii* or *M. testudineum*. Individuals were considered 'infected' if they tested positive for either pathogen. Previous research has documented relationships between gopher tortoise infection status and sex/life stage (Karlin, 2008; Wendland *et al.*, 2010), body condition (Cozad, 2018; Goessling *et al.*, 2019) and PCV (Cozad, 2018). In reptiles and birds more generally, increases in heterophils may be indicative of inflammation (Stacy *et al.*, 2011; Juul-Madsen *et al.*, 2014; Stacy *et al.*, 2017). Therefore, we included tortoise stage class (at time of recapture in 2017–2018), body condition, PCV, absolute

immature heterophils ($\times 10^3 \mu\text{l}^{-1}$), absolute total heterophils (immature and mature heterophils; $\times 10^3 \mu\text{l}^{-1}$), evidence of nasal discharge (present/absent), evidence of nasal erosion (present/absent) and ocular evidence of infection including ocular discharge, swelling or conjunctivitis (present/absent) as model parameters. We considered a null model containing no effects, all single parameter models, and all but two models formed from additive combinations of two parameters: because of evidence of strong collinearity between variables, we excluded the two models pairing immature with total heterophils and pairing PCV with total heterophils (Spearman's correlation test $\rho = 0.34$, $S = 203\,680$, $P < 0.001$; $\rho = 0.23$, $S = 23\,726$, $P < 0.01$). Although a larger list of candidate models could be generated through additional combinations of variables, we limited our consideration to a smaller set of candidate models that (1) related to previously suggested hypotheses or documented patterns and (2) had simple structure given the small number of positive animals. Because tortoises were placed in soft-release pens on site in groups prior to release, we originally included release pen as a random effect in all candidate models. However, because the estimated variance parameter for pen was essentially zero (indicating no detectable difference in infection probability among pen groups), we subsequently removed release pen from all models.

To compare candidate models, we fit models to data that contained a complete set of individual attributes for each tortoise. Due to few complete records for juveniles ($n = 2$) and subadults ($n = 14$), we combined these stages into a single group classified as 'immature' in all candidate models. To more easily make comparisons across models with different continuous variables, we centred and scaled continuous variables (PCV, body condition, immature heterophils, total heterophils) by subtracting the mean and dividing by the standard deviation (SD) of each variable. We used Akaike's Information Criteria corrected for small sample sizes (AICc) to compare candidate models (Hurvich and Tsai, 1989; Akaike, 1998). We report the results from all candidate models with a delta AIC < 2 . For all averaged observations we report the means \pm SD. We conducted all analyses in R version 4.0.2 (R Development Core Team, 2020) and used package Multimodel Inference ('MuMIn') version 1.43.17 for model selection (Barton, 2020).

Results

Visual health assessment

During 2017–2018, we captured 130 individuals at the AGTHP and received 13 additional waif tortoises for release at the preserve. In total, we visually assessed 143 individual tortoises (including 46 individuals that were assessed in both 2017 and 2018), comprising 68 females, 50 males, 17 subadults, 5 juveniles and 3 hatchlings (Table 2). Of the 63 tortoises assessed in 2017, 2 (3.1%) exhibited ocular abnormalities (discharge, swelling or redness), 3 (4.8%) had

nasal discharge and 4 (6.3%) had nasal erosion. In 2018, we assessed 126 individuals, of which 11 (8.7%) exhibited ocular abnormalities, 11 (8.7%) had nasal discharge and 14 had nasal erosion (11.1%). Of these animals with abnormalities, four exhibited both nasal discharge and erosion at the time of assessment, three exhibited both ocular abnormalities and nasal discharge, two individuals had both ocular abnormalities and nasal erosion and no individual exhibited all three abnormalities simultaneously. We did not observe any other substantial clinical abnormalities (e.g. recent shell or external injuries) or ectoparasites (including ticks) in either year. We did not see any individuals that appeared distressed at time of sample collection or that required veterinary intervention at the time of study. In addition to live animals, we also recovered the shells of nine deceased individuals over the course of the study. However, at the time of recovery, no soft tissue remained on the carcasses and no necropsies were possible.

Pathogen screening

In total, we screened 143 individuals with at least one swab type and obtained oral swabs from 139 of those individuals. Although we detected *Mycoplasma* spp. in both years, we did not detect any other pathogens of concern (including four species of *Ranavirus*) in our screenings (Table 1). In 2017, we tested 63 individuals using oral ($n = 59$), cloacal ($n = 62$) and/or nasal swabs ($n = 2$) for 13 pathogens (Table 1). In 2017, *M. agassizii* was the only pathogen detected, with a prevalence of 10.2% in the oral swabs [95% confidence interval (CI): 3.8–20.8%; $n = 6$ positive swabs]. We also detected *M. agassizii* in one nasal swab. This individual's oral swab was also positive, with the amount of DNA detected from the oral swab (15.1 copies/ μl) over 10 times greater than the amount detected from the nasal swab (1.4 copies/ μl ; Table 3). In 2018, we tested 124 individuals using oral ($n = 122$), cloacal ($n = 82$) and/or nasal swabs ($n = 4$) for 11 pathogens (Table 1). We detected *M. agassizii* with a prevalence of 13.9% (95% CI: 8.3–21.4%; $n = 17$ positive) and *M. testudineum* with a prevalence of 0.8% (95% CI: 0–4.5%; $n = 1$ positive) in oral swabs. No tortoise was concurrently infected with both pathogens. All four of the nasal swabs that tested positive for *M. agassizii* were from individuals whose oral swabs also tested positive for the pathogen. We only detected *M. agassizii* in cloacal swabs from three individuals that also had positive oral swabs (Table 3). In 2018, we also detected emydid *Mycoplasma* in the oral swab of a single tortoise, a naturally recruited hatchling (i.e. not a released animal), that showed no clinical evidence of infection. Swabs collected in 2017 were not screened for this pathogen.

We collected and analysed oral swabs from 42 tortoises in both 2017 and 2018. Of these 42 resampled animals, 6 individuals changed infection status between years. Two individuals that were positive for *M. agassizii* in 2017 were negative in 2018. Both had low copy numbers of pathogen DNA detected in 2017 (Table 3). Four individuals were negative for all pathogens in 2017 but tested positive for

Table 2: Mean (and range) gopher tortoise morphometric measurements and hemogram data by demographic stage class during the 2017–2018 sampling period at the AGTHP in South Carolina, USA.

| Parameter | Tortoise stage class | | | | | | | | | | | |
|--|----------------------|-------------------------|----------|--------------------------|----------|---------------------------|------------|-----------------------------|--------------|-----------------------------|----|-----------------------------|
| | Hatchling | | Juvenile | | Subadult | | Adult male | | Adult female | | n | Mean ± 1 SD (range) |
| | n | Mean ± 1 SD (range) | n | Mean ± 1 SD (range) | n | Mean ± 1 SD (range) | n | Mean ± 1 SD (range) | n | Mean ± 1 SD (range) | | |
| Morphometrics | | | | | | | | | | | | |
| MCL (mm) | 3 | 51.3 ± 8.0 (43–59) | 5 | 114.6 ± 15.2 (92–128) | 17 | 183.6 ± 26.4 (145–227) | 50 | 278.9 ± 25.1 (225–340) | 68 | 285.7 ± 28.1 (221–355) | 68 | 278.9 ± 25.1 (225–340) |
| Mass (g) | 3 | 34.0 ± 13.7 (22–49) | 5 | 281.2 ± 105.2 (135–382) | 17 | 1151.8 ± 482.4 (566–1960) | 50 | 4112.0 ± 1079.4 (1972–7237) | 68 | 4240.4 ± 1232.5 (1910–7428) | 68 | 4112.0 ± 1079.4 (1972–7237) |
| Body condition (g/mm ³) | 3 | 1.05 ± 0.09 (0.95–1.11) | 5 | 1.01 ± 0.03 (0.98–1.05) | 17 | 1.05 ± 0.08 (0.84–1.18) | 49 | 1.08 ± 0.12 (0.63–1.57) | 67 | 1.05 ± 0.13 (0.62–1.79) | 67 | 1.08 ± 0.12 (0.63–1.57) |
| Haematology | | | | | | | | | | | | |
| PCV (%) | | — | 4 | 20.3 ± 5.4 (16–28) | 15 | 25.7 ± 7.2 (12–34) | 47 | 29.2 ± 6.2 (14–38) | 66 | 27.8 ± 5.6 (12–44) | 66 | 29.2 ± 6.2 (14–38) |
| Total protein (g L ⁻¹) | | — | 2 | 21.5 ± 2.1 (20–23) | 13 | 30.6 ± 7.9 (20–45) | 47 | 37.9 ± 7.4 (20–57) | 64 | 38.0 ± 6.9 (20–55) | 64 | 37.9 ± 7.4 (20–57) |
| White blood cell Count (× 10 ³ μl ⁻¹) | | — | 3 | 9.60 ± 2.02 (7.30–11.10) | 15 | 10.60 ± 3.96 (5.60–21.10) | 46 | 9.51 ± 3.49 (5.20–19.80) | 65 | 9.60 ± 3.32 (4.60–21.20) | 65 | 9.51 ± 3.49 (5.20–19.80) |
| Total heterophils (× 10 ³ μl ⁻¹) | | — | 3 | 3.96 ± 0.06 (3.90–4.00) | 15 | 4.13 ± 2.15 (1.40–8.30) | 46 | 4.00 ± 1.92 (0.71–8.90) | 65 | 4.05 ± 1.83 (1.35–11.21) | 65 | 4.00 ± 1.92 (0.71–8.90) |
| Mature heterophils (× 10 ³ μl ⁻¹) | | — | 3 | 3.87 ± 0.15 (3.70–4.00) | 15 | 3.91 ± 2.10 (1.40–8.30) | 46 | 3.88 ± 1.91 (0.71–8.90) | 65 | 3.95 ± 1.84 (1.30–11.00) | 65 | 3.88 ± 1.91 (0.71–8.90) |
| Immature heterophils (× 10 ³ μl ⁻¹) | | — | 3 | 0.10 ± 0.17 (0.00–0.29) | 15 | 0.22 ± 0.30 (0.0–0.89) | 46 | 0.11 ± 0.11 (0.0–0.42) | 65 | 0.15 ± 0.20 (0.00–1.20) | 65 | 0.11 ± 0.11 (0.0–0.42) |
| Lymphocytes (× 10 ³ μl ⁻¹) | | — | 3 | 3.80 ± 0.78 (2.90–4.30) | 15 | 3.68 ± 1.44 (2.0–7.0) | 46 | 3.30 ± 1.11 (0.90–5.70) | 65 | 3.32 ± 1.12 (1.50–6.00) | 65 | 3.30 ± 1.11 (0.90–5.70) |
| Monocytes (× 10 ³ μl ⁻¹) | | — | 3 | 1.03 ± 0.86 (0.37–2.00) | 15 | 1.05 ± 0.99 (0.10–4.20) | 46 | 0.88 ± 0.63 (0.07–3.10) | 65 | 0.76 ± 0.5 (0.05–2.60) | 65 | 0.88 ± 0.63 (0.07–3.10) |
| Eosinophils (× 10 ³ μl ⁻¹) | | — | 3 | 0.34 ± 0.28 (0.07–0.62) | 15 | 0.61 ± 0.71 (0.00–2.60) | 46 | 0.44 ± 0.37 (0.00–1.50) | 65 | 0.54 ± 0.69 (0.00–3.70) | 65 | 0.44 ± 0.37 (0.00–1.50) |
| Basophils (× 10 ³ μl ⁻¹) | | — | 3 | 0.51 ± 0.55 (0.00–1.10) | 15 | 1.20 ± 0.95 (0.00–2.90) | 46 | 0.89 ± 0.79 (0.07–4.80) | 65 | 0.95 ± 0.76 (0.06–4.10) | 65 | 0.89 ± 0.79 (0.07–4.80) |
| Hi:L ratio | | — | 3 | 1.08 ± 0.26 (0.93–1.38) | 15 | 1.24 ± 0.72 (0.23–3.07) | 46 | 1.38 ± 0.88 (0.23–4.63) | 65 | 1.37 ± 0.79 (0.38–4.09) | 65 | 1.38 ± 0.88 (0.23–4.63) |

If multiple records of the same individual occurred during the sampling period, they were averaged prior to their incorporation into the stage class summary statistics. SDs and number of individuals (n) in each calculation are also provided.

Table 3: Individual gopher tortoises from the Aiken Gopher Tortoises Heritage Preserve in Aiken County, SC, USA for which pathogens were detected in oral, cloacal or nasal swabs submitted to the Wildlife Epidemiology Laboratory at the University of Illinois.

| ID | Swab type | Year | DNA (ng/ μ l) | Pathogen | Pathogen copy numbers | |
|--------------------|-----------|------|-------------------|-----------------------|-----------------------|-----------------|
| | | | | | (Copies/ μ l rxn) | (Copies/ng DNA) |
| 19 | Oral | 2017 | 2.25 | <i>M. agassizii</i> | 8967.12 | 1594.16 |
| 416 | Oral | 2017 | 3.26 | <i>M. agassizii</i> | 25507.59 | 3129.77 |
| 421 ^b | Oral | 2017 | 5.25 | <i>M. agassizii</i> | 119.25 | 9.09 |
| 436 ^{a,b} | Nasal | 2017 | 2.62 | <i>M. agassizii</i> | 8.88 | 1.36 |
| 436 ^{a,b} | Oral | 2017 | 4.73 | <i>M. agassizii</i> | 178.47 | 15.09 |
| 542 | Oral | 2017 | 5.37 | <i>M. agassizii</i> | 88.68 | 6.61 |
| 672 | Oral | 2017 | 1.65 | <i>M. agassizii</i> | 14128.87 | 3425.18 |
| 16 ^c | Oral | 2018 | 5.92 | <i>M. testudineum</i> | 70.57 | 4.77 |
| 19 | Oral | 2018 | 4.45 | <i>M. agassizii</i> | 31262.45 | 2810.11 |
| 416 | Oral | 2018 | 36.05 | <i>M. agassizii</i> | 602801.50 | 6688.50 |
| 469 | Oral | 2018 | 11.94 | <i>M. agassizii</i> | 23.59 | 0.79 |
| 546 ^a | Oral | 2018 | 38.58 | <i>M. agassizii</i> | 14.88 | 0.15 |
| 546 ^a | Nasal | 2018 | 5.23 | <i>M. agassizii</i> | 75.06 | 5.74 |
| 591 | Oral | 2018 | 5.26 | <i>M. agassizii</i> | 10.64 | 0.81 |
| 595 | Oral | 2018 | 10.53 | Emydid Myco. | 11.73 | 0.45 |
| 603 ^c | Oral | 2018 | 29.68 | <i>M. agassizii</i> | 33878.50 | 456.58 |
| 626 | Oral | 2018 | 3.32 | <i>M. agassizii</i> | 39.14 | 4.72 |
| 639 ^c | Oral | 2018 | 4.17 | <i>M. agassizii</i> | 4017.15 | 385.34 |
| 645 | Oral | 2018 | 10.37 | <i>M. agassizii</i> | 545.37 | 21.04 |
| 646 | Oral | 2018 | 5.43 | <i>M. agassizii</i> | 34.33 | 2.53 |
| 666 ^{a,c} | Nasal | 2018 | 3.97 | <i>M. agassizii</i> | 518.24 | 52.22 |
| 666 ^{a,c} | Oral | 2018 | 17.89 | <i>M. agassizii</i> | 52879.92 | 1182.33 |
| 667 ^a | Cloacal | 2018 | 3.67 | <i>M. agassizii</i> | 2541.16 | 276.97 |
| 667 ^a | Nasal | 2018 | 3.67 | <i>M. agassizii</i> | 40436.56 | 4407.25 |
| 667 ^a | Oral | 2018 | 7.31 | <i>M. agassizii</i> | 63708.83 | 3486.12 |
| 672 | Oral | 2018 | 21.04 | <i>M. agassizii</i> | 101294.60 | 1925.75 |
| 678 | Oral | 2018 | 11.49 | <i>M. agassizii</i> | 2262.58 | 78.77 |
| 689 | Oral | 2018 | 10.35 | <i>M. agassizii</i> | 9.06 | 0.35 |
| 691 ^a | Cloacal | 2018 | 5.10 | <i>M. agassizii</i> | 70.95 | 5.56 |
| 691 ^a | Oral | 2018 | 2.10 | <i>M. agassizii</i> | 3370.64 | 642.03 |
| 694 ^a | Cloacal | 2018 | 10.73 | <i>M. agassizii</i> | 103.75 | 3.87 |
| 694 ^a | Nasal | 2018 | 5.71 | <i>M. agassizii</i> | 321.03 | 22.49 |
| 694 ^a | Oral | 2018 | 6.92 | <i>M. agassizii</i> | 2347.44 | 135.69 |

Using qPCR, pathogen load was quantified for individuals positive for URTD-associated pathogen (*M. agassizii*, *M. testudineum*) infections in 2017 and 2018. Two individuals (421 and 436) had relatively low pathogen copy numbers in 2017 (9.09 and 1.36 copies/ng DNA) before testing negative in 2018. A single tortoise tested positive for emydid *Mycoplasma* in 2018 but showed no evidence of clinical disease. This pathogen was not included in the 2017 panel.

^aIndividuals with more than one sample type.

^bIndividuals who converted from positive status in 2017 to negative status in 2018.

^cIndividuals who converted from negative status in 2017 to positive status in 2018.

Table 4: Top 15 candidate models used to identify predictors of *Mycoplasma* spp. infection in gopher tortoises at the AGTHP in Aiken County, SC, USA.

| Model | Intercept | Df | AICc | Delta | Weight | ND | NE | O | Sex | BC | PCV | Im.het | Het |
|-------------|-----------|----|-------|-------|--------|----|----|---|-----|-------|-------|--------|------|
| ND | -2.24 | 2 | 88.81 | 0.00 | 0.224 | • | | | | | | | |
| ND + Sex | -2.86 | 4 | 89.19 | 0.38 | 0.185 | • | | | • | | | | |
| ND + Im.het | -2.25 | 3 | 90.02 | 1.21 | 0.122 | • | | | | | | 0.24 | |
| ND + BC | -2.25 | 3 | 90.50 | 1.69 | 0.096 | • | | | | -0.20 | | | |
| ND + PCV | -2.24 | 3 | 90.70 | 1.89 | 0.087 | • | | | | | -0.14 | | |
| ND + NE | -2.21 | 3 | 90.74 | 1.92 | 0.085 | • | • | | | | | | |
| ND + Het | -2.24 | 3 | 90.77 | 1.96 | 0.084 | • | | | | | | | 0.11 |
| ND + O | -2.26 | 3 | 90.81 | 2.00 | 0.082 | • | | • | | | | | |
| Null model | -1.90 | 1 | 97.12 | 8.31 | 0.004 | | | | | | | | |
| Im.het | -1.94 | 2 | 97.36 | 8.55 | 0.003 | | | | | | | 0.31 | |
| BC | -1.93 | 2 | 98.16 | 9.35 | 0.002 | | | | | -0.29 | | | |
| O | -1.98 | 2 | 98.28 | 9.47 | 0.002 | | | • | | | | | |
| BC + Im.het | -1.97 | 3 | 98.50 | 9.69 | 0.002 | | | | | -0.28 | | 0.31 | |
| O + Im.het | -2.02 | 3 | 98.52 | 9.71 | 0.002 | | | • | | | | 0.32 | |
| Sex | -2.27 | 3 | 98.78 | 9.96 | 0.002 | | | | • | | | | |

Categorical variables included nasal discharge (ND), nasal erosion (NE), ocular clinical abnormalities (O) and sex and/or stage of the tortoise (Sex). Continuous variables included body condition (BC), PCV, immature heterophils (Im.Het) and total heterophils (Het)—all centred to their means and standardized to their SD. Categorical variables included in each model are denoted by a ‘•’. Continuous variables included in models are represented by their estimated slope on the logit scale. Akaike Information Criteria corrected for small sample sizes (AICc) was used for model selection, and models are ordered by model weight.

URTD-associated pathogens in 2018—three for *M. agassizii* and one for *M. testudineum*.

Hemogram evaluation and hemoparasite quantification

In total, we collected blood from 132 individuals. All haematological data are presented by life stage in Table 2. Blood films from 57 individuals in 2017 and 72 individuals in 2018 were reviewed. In 2017, no infectious agents, including no evidence suggestive of *Anaplasma* spp., were detected. In 2018, rare hemogregarine infections were identified (<1 infected RBC/100 RBC) in two adult individuals (prevalence = 2.6%) with PCV of 29 and 31%, respectively. Anisocytosis (variation in red blood size) was characterized as ‘absent’ in 94 individuals, ‘mild’ in 33 individuals and ‘moderate’ in two individuals. Polychromasia (presence of immature red blood cells) was considered ‘absent’ in 99 individuals, ‘mild’ in 28 individuals and ‘moderate’ in two individuals. Overt morphological abnormalities in WBCs were not detected in any of the tortoises. Thrombocytes were considered adequate in all individuals.

Modelling predictors of infection with *Mycoplasma* pathogens

For 123 tortoises with complete sets of predictor variables [107 negative, 16 positive for either *M. agassizii* ($n = 15$) or

M. testudineum ($n = 1$)], we fit data to 35 candidate models (Table 4). We found the presence of nasal discharge to be the most important predictor of infection, as it was the sole parameter in the top model (22.4% model weight) and the only factor identified as a significant predictor of infection ($P < 0.001$; Table 4; Fig. 1). Additionally, nasal discharge appeared in the top 8 models, which collectively accounted for >96.6% of model weight. We observed nasal discharge in 31.3% of positive animals and 3.7% of negative animals. The second most supported model (18.5% model weight) included the additive effects of tortoise stage class and nasal discharge (Table 4). Although the point estimate for the infection probability in immature tortoises was slightly higher than the infection probability of adult males and adult females, there was substantial variation in infection probability (Fig. 1). The third best model (12.2% model weight) included the additive effects of nasal discharge and immature heterophils ($\times 10^3 \mu\text{l}^{-1}$), and model estimates indicated a positive relationship between absolute immature heterophils and infection probability (Table 4; Fig. 2). Models with the additive effect of nasal discharge and body condition, nasal discharge and PCV, nasal discharge and nasal erosion, nasal discharge and total heterophils and nasal discharge and ocular evidence of infection all received a similar weight, suggesting a high level of uncertainty among alternative models containing the nasal discharge predictor (Table 4).

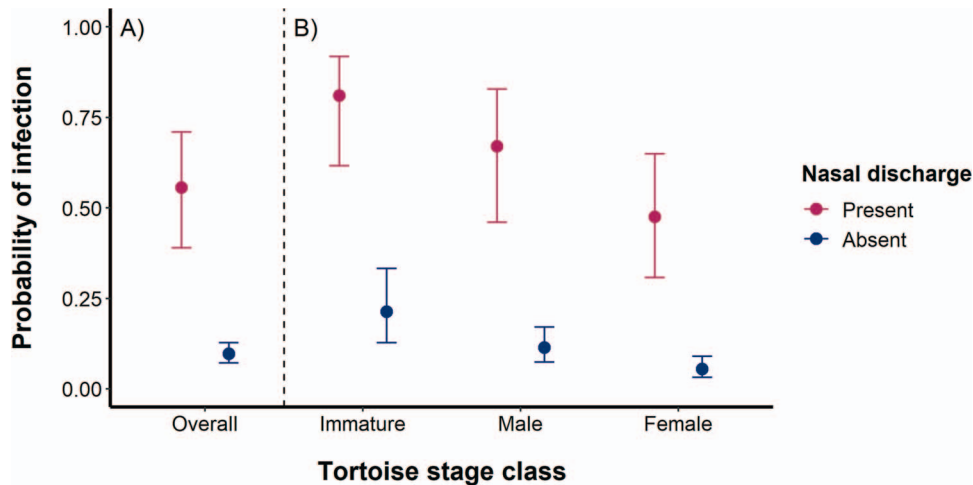


Figure 1: Model estimates of gopher tortoise probability of infection with *Mycoplasma* spp. based on the top model—a single parameter model that included the presence or absence of nasal discharge (A). The second-best model included the additive effects of the presence of nasal discharge and tortoise stage (B). Infection status was determined through qPCR on oral swabs collected in 2017 and 2018 from tortoises at the AGTHP (Aiken County, SC, USA). Error bars indicate SE for the model predictions.

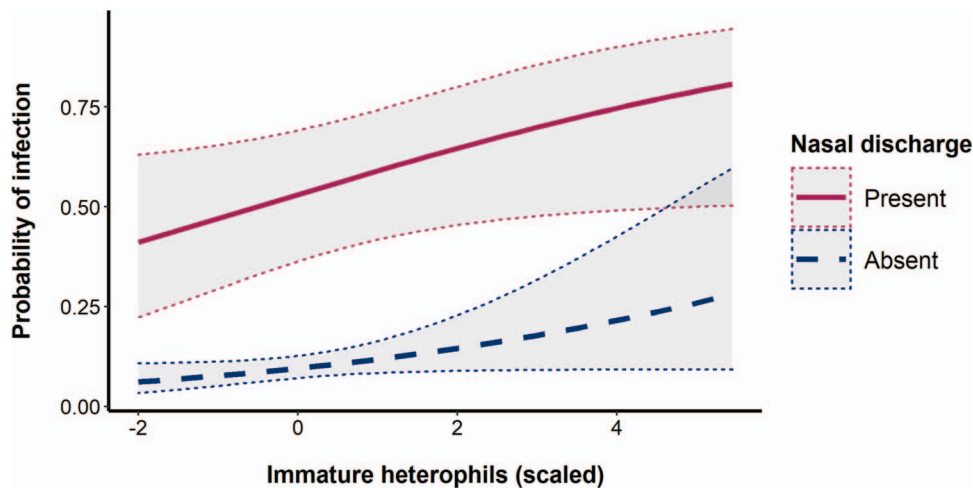


Figure 2: Model estimates of gopher tortoise probability of infection with *Mycoplasma* spp. based on the additive effects of the presence of nasal discharge and scaled immature heterophils ($\times 10^3 \mu\text{l}^{-1}$). Immature heterophils were scaled by subtracting the mean and dividing by the standard deviations. Infection status was determined through qPCR on oral swabs collected in 2017 and 2018 from tortoises at the AGTHP (Aiken County, SC). Dotted lines outside shaded grey shading indicate SE for the model predictions.

Discussion

Our study is the first to assess the health of gopher tortoises in a population established almost entirely through the release of waif animals. Overall, most captured individuals appeared clinically normal. Despite the varied, often unknown histories of individual animals, we detected very few pathogens in this unique and isolated population. We documented the presence of only two known tortoise pathogens, *M. agassizii* with 10.2% and 13.9% prevalence and *M. testudineum* with 0.0% and 0.8% prevalence in 2017 and 2018, respectively. These pathogens appear to be common in wild gopher tortoise pop-

ulations (McCoy *et al.*, 2007; Berish *et al.*, 2010; Goessling *et al.*, 2019), and prior exposure has been documented in wild populations throughout much of the tortoise's range, including Florida (Karlin, 2008; Ozgul *et al.*, 2009), Georgia (McGuire *et al.*, 2014), Louisiana (Diaz-Figueroa, 2005), Mississippi (Smith *et al.*, 1998) and Alabama (Goessling *et al.*, 2019). However, prevalence varies substantially among populations, with some populations having either very low (0–3%) or very high seroprevalence (96%–100%; McGuire *et al.*, 2014). In a recent study that used qPCR to evaluate *M. agassizii* infection in seven Alabama tortoise populations, prevalence rates ranged from 0% to 6%

(Goessling *et al.*, 2019). For a translocated population in Florida that also used qPCR, *M. agassizii* prevalence was estimated to be 20% (Cozad *et al.*, 2020b). Prior research specifically on waif tortoises is limited, but the few existing studies that have identified *M. agassizii* in waif tortoises have also observed a relatively low number of positive individuals (Whitfield *et al.*, 2018; Elbers and Taylor, 2019).

We found that presence of nasal discharge was an important (but imperfect) clinical predictor of current infection with URTD-associated pathogens, as has been previously reported in both gopher tortoises and desert tortoises (Schumacher *et al.*, 1997; Karlin 2008; Berish *et al.*, 2010). Previous research has shown that nasal discharge may appear more quickly post-infection than other metrics such as antibody presence (Brown *et al.*, 1999; Brown *et al.*, 2002; Aiello *et al.*, 2019; Drake *et al.*, 2019); thus, presence of nasal discharge may be a useful screening tool for identifying candidates to quarantine, determining suitability of tortoises for release or prioritizing individuals for pathogen testing. Nasal erosion and ocular evidence of infection appeared to be less important predictors of active infection. The presence of nasal discharge appeared in the eight best models, while nasal erosion and ocular evidence of infection appeared only in the sixth and eighth model, respectively (Table 4). Only three of the 21 animals positive for either pathogen exhibited ocular evidence of infection and these individuals also had nasal discharge. Similarly, ocular abnormalities were found to be unreliable predictors of *Mycoplasma* spp. infection in Mojave desert tortoises (Burgess *et al.*, 2021). Although nasal erosion was a weaker predictor of current infection, it likely provides useful information on prior pathogen exposure, as it has been shown to be positively correlated with the presence of *M. agassizii* antibodies (Goessling *et al.*, 2019). Because URTD is a recrudescence disease where tortoises can begin shedding bacteria again (Sandmeier *et al.*, 2017), evidence of prior infection may still be informative for management or for screening acquired waif gopher tortoises for potential release.

Despite the attention URTD has received in scientific literature, the overall effects of the disease in *Gopherus* tortoises are still debated (Sandmeier *et al.*, 2009; Berish *et al.*, 2010). In many cases, URTD appears to have only limited effects on tortoise survival (Karlin, 2008; Ozgul *et al.*, 2009) and population persistence (McCoy *et al.*, 2007). Rarely, however, URTD has been implicated in mortality events (Jacobson *et al.*, 1991b; Gates *et al.*, 2002; Seigel *et al.*, 2003). In our study, the majority of infected individuals were carriers of the pathogen without any evidence of clinical disease and were clinically normal. However, we noticed a high rate of infected tortoises in a single soft-release pen (pen 10), with 50% ($n = 6/12$) of sampled individuals testing positive in either 2017 or 2018 for *M. agassizii*. Of the nine shells recovered during the study period, eight were recovered from this pen. Considering that 22 animals (12 adults) had been released during 2016–2017, there was at least a 36% mortality rate for this pen. Because seven out of eight of these

individuals died before the study, we cannot conclude with certainty that the higher mortality in pen 10 was the result of a specific pathogen, and which other factors may have played a role. Non-infectious factors, such as stress associated with release density, have been linked to increased mortality in other translocated populations (Cozad *et al.*, 2020a). However, at AGTHP, release densities and conditions were similar for all cohorts, and we did not observe high mortality rates for the population as a whole (McKee *et al.*, 2021). Therefore, we suspect *M. agassizii* may have contributed to the higher mortality rate observed in pen 10. Although we captured seemingly healthy animals positive for URTD-associated pathogens, similar variability in host response has been noted in desert tortoises experimentally infected with the pathogen (Aiello *et al.*, 2019). Prior research suggests that high morbidity is related to high prevalence, indicating an effect of pathogen load in populations (Sandmeier *et al.*, 2017). Because there was a higher prevalence observed in pen 10 relative to the rest of the population, individuals in this pen may have exhibited worse outcomes than infected individuals elsewhere on the preserve. Variability in pathogen strain can also result in different virulence patterns (Perez *et al.*, 2020), and additional work is likely needed to better characterize the genetic diversity of URTD-associated pathogens as it relates to virulence (Weitzman *et al.*, 2017).

Given prior findings that immature gopher tortoises are less likely to be infected with *Mycoplasma* spp. than adults (Karlin, 2008; Wendland *et al.*, 2010; Page-Karjian *et al.*, 2021), it is unexpected that our model estimated infection probability to be higher for younger animals. Because this population is comprised of waif animals that were previously housed in captive facilities, normal exposure patterns could have been altered by increased contact associated with shared housing and provisioning for individuals across life stages while in captivity. Additionally, prior studies have used antibody presence to determine the exposure status of individuals, which captures prior exposure but is not always indicative of current shedding of the pathogen (McCoy *et al.*, 2007; Wendland *et al.*, 2010; McGuire *et al.*, 2014; Aiello *et al.*, 2019). As pathogen screening using qPCR analysis of swabs becomes more common in health assessment studies, we will be able to better compare our results to other gopher tortoise populations.

There is growing interest in using readily available diagnostic tools such as haematology to understand inflammation as it relates to stress, immune functions and infection status in reptiles (Sandmeier *et al.*, 2018; Rosenberg *et al.*, 2018a; Neuman-Lee *et al.*, 2019; Sandmeier *et al.*, 2019a). Although inference from our results is limited by a low number of pathogen-positive animals, we observed a positive correlation between absolute immature heterophils and probability of infection with URTD-associated pathogens (Fig. 2). This finding supports previous reports that immature heterophils play an important role in assessing clinical status and active inflammation in *Gopherus* spp. tortoises (Stacy *et al.*, 2017;

Rosenberg *et al.*, 2018a; Sandmeier *et al.*, 2019a). In the congeneric Mojave desert tortoise, haematological abnormalities were present in tortoises with clinical signs of infection with *M. agassizii* (Christopher *et al.*, 2003). Future studies that include a larger sample size of *Mycoplasma* spp.-positive animals could help clarify the relationship between infection status, number of immature heterophils and other haematological and immune function analytes. Understanding these analytes and their significance for population health in endangered species will become increasingly important for identifying stressors and other specific impacts that could require targeted mitigation strategies and conservation efforts (Ohmer *et al.*, 2021).

In addition to the two known tortoise pathogens, we also documented the presence of emydid *Mycoplasma* in a single individual (an unmarked, naturally recruited hatchling in 2018). This pathogen was first documented in eastern box turtles (*Terrapene carolina carolina*; Feldman *et al.*, 2006). Since its discovery, it has been documented in many North American chelonians and usually does not cause disease (Ossiboff *et al.*, 2015; Sandmeier *et al.*, 2019b). The pathogen copy numbers in this individual were very low (0.45 copies/ng DNA) and the tortoise showed no evidence of clinical disease. Given the low copy numbers, it is possible the individual was not actually infected by the pathogen and we detected it due to contamination of the sample or non-infected passage of a *Mycoplasma* from a shared environment with an emydid host (e.g. box turtle). However, no other known tortoise pathogens, including *Ranavirus* spp., were detected in our study.

Stress has often been cited as a concern with translocation efforts (Teixeira *et al.*, 2007; Dickens *et al.*, 2010), particularly in circumstances that involve the release of formerly captive individuals. The H:L ratios documented in the AGTHP population (1.35 ± 0.81) were similar to values reported in other translocated populations (1.98 ± 0.96 ; Cozad, 2018) and for wild gopher tortoises in Florida (0.32–2.88; Page-Karjian *et al.*, 2021) and Mississippi (1.15 ± 0.87 and 2.08 ± 1.31 , Holbrook, 2015). Although there are few studies for comparison, particularly from wild *in situ* populations, comparison with reported values suggests that on average, translocated waif tortoises have similar H:L ratios to their wild counterparts.

Despite our efforts to check traps multiple times throughout the day, blood sampling occurred at the end of the day after animals were transported to the laboratory, resulting in a time lag of several hours between capture and blood collection; these aspects in addition to handling of animals could have affected hemogram results (e.g. caused some degree of distress). A recent study that collected blood samples in the field within 3 mins of handling observed an average H:L ratio below 1.0 (Goessling and Mendonça, 2021), with lowest H:L ratios in less distressed groups (e.g. untrapped, hand-captured tortoises). This finding suggests that H:L ratios we observed,

although similar to those reported in the literature, may be elevated due to acute capture effects and not reflective of a true physiological baseline. Indeed, only 42% of the calculated H:L ratios fell below 1.0. Because temperature, season, capture techniques, individual variation, sample collection protocols and analytical methods can influence haematological data (Goessling *et al.*, 2016; Rosenberg *et al.*, 2018a; Rosenberg *et al.*, 2018b; Sandmeier *et al.*, 2019a), caution is always warranted when making comparisons among studies. However, quantifying immature heterophils can aid in interpreting H:L ratios and distinguishing between stress (characterized by increased mature heterophils) and inflammation (as indicated by increased immature heterophils and/or presence of toxic change) (Stacy *et al.*, 2022).

Outside of its potential relationships with inflammation, concern for underlying infection, and/or stress, haematological analysis can provide additional insight into the overall health of individuals. Despite the diversity of backgrounds and unique nature of this population, the hemogram data we observed in this study closely aligned with previously reported reference intervals for a wild gopher tortoise population in southeastern Florida (Page-Karjian *et al.*, 2021). The hemogram data of the majority of adult tortoises (>85%) fell within reference intervals for PCV, TP, WBC count, H:L ratio and absolute heterophils, lymphocytes, monocytes and basophils. Interestingly, adult gopher tortoises from southeastern Florida had comparatively higher eosinophils than our waif tortoises, which could suggest antigenic stimulation in the Florida population, as it also documented a higher prevalence of URTD and individuals infected with *Anaplasma* spp. (Stacy *et al.*, 2011; Page-Karjian *et al.*, 2021); although the latter pathogen was not evaluated by PCR in our study, there was no evidence by blood film evaluation.

The health assessment data we present for waif gopher tortoises released to a wildlife preserve over the course of a decade are comparable with data for their wild counterparts. Despite the population being largely comprised of waif tortoises—individuals that are considered at higher risk due to factors such as time in captivity or unknown origin—we did not detect any unexpected pathogens and the prevalence of URTD-associated pathogens was comparable with the prevalence reported in wild *in situ* populations. Although the AGTHP population appears healthy overall, it is important to consider that health assessments and pathogen screenings occurred up to 11 years following release. Of the 203 juvenile, subadult and adult waif tortoises released into the population prior to 2017, we recaptured 107 of them (53%; McKee *et al.*, 2021). Certainly, mortality accounts for some portion of the animals we failed to recapture, and we acknowledge that some individuals infected with pathogens may have died prior to our survey. However, long-term survival estimates from this population are comparable with wild *in situ* populations (McKee *et al.*, 2021) and do not provide any indication of widespread mortality.

Conclusions

Collectively, our results suggest that waif gopher tortoises can play an important role in the recovery and sustainability of isolated populations that are far below the threshold of viability (McKee *et al.*, 2021). As suitable tortoise habitat becomes increasingly fragmented, there may be additional opportunities to introduce waif tortoises to isolated sites without jeopardizing the health of resident or neighbouring populations. Quarantine practices, pathogen screening and visual assessment prior to release, along with post-release monitoring are important measures that can reduce the risks associated with the release of formerly captive individuals. Because the species is declining (Smith *et al.*, 2006), the risk of potential adverse health impacts will likely need to be balanced with the need for increasing the number of populations and the number of reproductive adults in existing populations of this long-lived species, which may require up to 20 years to reach maturity (Diemer, 1986). Moreover, as the demand for turtles and tortoises has resulted in the ongoing illegal collection and confiscation of many other species around the globe (Rosen and Smith, 2010; Bush *et al.*, 2014; Mendiratta *et al.*, 2017), it is important to understand how to best use these formerly captive individuals (particularly reproductive adults) for conservation objectives. As one of the first studies to assess the health of a population augmented with formerly captive chelonians, our findings provide important insight for other species facing similar management dilemmas.

Funding

This work was supported by the United States Fish and Wildlife Service and SCDNR [SC-E-F17AP00226], Warnell School of Forestry and Natural Resources, Animal Welfare Institute, Riverbanks Zoo and Garden, American Museum of Natural History, Gopher Tortoise Council, and Cooperative Agreement # DE-EM0004391 from Department of Energy to the University of Georgia Research Foundation. Any use of trade, firm or product names is for descriptive purposes only and does not imply endorsement by the U.S. Government.

Data Availability

The data underlying this article will be shared on request to the corresponding author.

Author Contributions

R.M., K.B. and T.T. acquired funding for research, conducted fieldwork and visually assessed tortoises. C.M. assisted with statistical analysis and study design. N.S. analysed blood films and provided expertise in interpreting haematological results. M.A. performed pathogen screening. R.M. drafted the original manuscript. All authors revised, contributed to and approved the final manuscript.

Acknowledgements

We thank Kyle Brown, Marionna Cane, Jonathan Cooley, Heather Gaya, David Haskins, Pearson McGovern, Caitlynn McNeil, Caleigh Quick, Amelia Russell and Nicole White for their assistance with fieldwork. The following current and former personnel from SCDNR were instrumental in managing the preserve and providing logistical and technical support for the project: Steve Bennett, Will Dillman, Andrew Grosse, Barry Kesler, Brett Moule, Johnny Stowe and Hunter Young. The population augmentation efforts were made possible by an Memorandum of Understanding between Florida Fish and Wildlife Conservation Commission and SCDNR and contribution of additional waif tortoises from other states. We thank Kristina Drake and two anonymous reviewers for their constructive feedback on the manuscript.

Supplementary material

Supplementary material is available at *Conservation Physiology* online.

References

- Aiello CM, Esque TC, Nussear KE, Emblidge PG, Hudson PJ (2019) The slow dynamics of mycoplasma infections in a tortoise host reveal heterogeneity pertinent to pathogen transmission and monitoring. *Epidemiol Infect* 147: E12. <https://doi.org/10.1017/S0950268818002613>.
- Aiello CM, Nussear KE, Walde AD, Esque TC, Emblidge PG, Sah P, Bansal S, Hudson PJ (2014) Disease dynamics during wildlife translocations: disruptions to the host population and potential consequences for transmission in desert tortoise contact networks. *Anim Conserv* 17: 27–39. <https://doi.org/10.1111/acv.12147>.
- Akaike H (1998) A new look at the statistical model identification. In E Parzen, K Tanabe, G Kitagawa, eds, *Selected Papers of Hirotugu Akaike*. Springer, New York, NY, pp. 215–222
- Alvarez WA, Gibbons PM, Rivera S, Archer LL, Childress AL, Wellehan JFX (2013) Development of a quantitative PCR for rapid and sensitive diagnosis of an intranuclear coccidian parasite in Testudines (TINC), and detection in the critically endangered Arakan forest turtle (*Heosemys depressa*). *Vet Parasitol* 193: 66–70. <https://doi.org/10.1016/j.vetpar.2012.11.029>.
- Aresco MJ, Guyer C (1999) Growth of the tortoise *Gopherus polyphemus* in slash pine plantations of southcentral Alabama. *Herpetologica* 55: 499–506.
- Barton K (2020) MuMIn: multi-model inference. R-package version 1.43.17. <https://CRAN.R-project.org/package=MUMIN>.
- Bell TP, Herbert SM (2017) Establishment of a self-sustaining population of a long-lived, slow-breeding gecko species (Diplodactylidae: *Hoplodactylus duvaucelii*) evident 15 years after translocation. *J Herpetol* 51: 37–46. <https://doi.org/10.1670/15-106>.

- Berish JE, Wendland LD, Kiltie RA, Garrison EP, Gates CA (2010) Effects of mycoplasmal upper respiratory tract disease on morbidity and mortality of gopher tortoises in northern and central Florida. *J Wildl Dis* 46: 695–705. <https://doi.org/10.7589/0090-3558-46.3.695>.
- Berry KH, Coble AA, Yee JL, Mack JS, Perry WM, Anderson KM, Brown MB (2015) Distance to human populations influences epidemiology of respiratory disease in desert tortoises. *J Wildl Mgmt* 79: 122–136. <https://doi.org/10.1002/jwmg.816>.
- Berry KH, Yee JL, Shields TA, Stockton L (2020) The catastrophic decline of tortoises at a fenced natural area. *Wildl Monogr* 205: 1–53. <https://doi.org/10.1002/wmon.1052>.
- Biggins DE, Godbey JL, Horton BM, Livieri TM (2011) Movements and survival of black-footed ferrets associated with an experimental translocation in South Dakota. *J Mammal* 92: 742–750. <https://doi.org/10.1644/10-MAMM-S-152.1>.
- Braun J, Schrenzel M, Witte C, Gokool L, Burchell J, Rideout BA (2014) Molecular methods to detect *Mycoplasma* spp. and Testudinid herpesvirus 2 in desert tortoises (*Gopherus agassizii*) and implications for disease management. *J Wildl Dis* 50: 757–766. <https://doi.org/10.7589/2013-09-231>.
- Brown DR, Merritt JL, Jacobson ER, Klein PA, Tully JG, Brown MB (2004) *Mycoplasma testudineum* sp. nov., from a desert tortoise (*Gopherus agassizii*) with upper respiratory tract disease. *Int J Syst Evol Microbiol* 54: 1527–1529. <https://doi.org/10.1099/ijs.0.63072-0>.
- Brown DR, Schumacher IM, McLaughlin GS, Wendland LD, Brown ME, Klein PA, Jacobson ER (2002) Application of diagnostic tests for mycoplasmal infections of desert and gopher tortoises with management recommendations. *Chelonian Conserv Biol* 4: 497–507.
- Brown MB, McLaughlin GS, Klein PA, Crenshaw BC, Schumacher IM, Brown DR, Jacobson ER (1999) Upper respiratory tract disease in the gopher tortoise is caused by *Mycoplasma agassizii*. *J Clin Microbiol* 37: 2262–2269. <https://doi.org/10.1128/JCM.37.7.2262-2269.1999>.
- Burgess TL, Braun J, Witte CL, Lamberski N, Field KJ, Allison LJ, Averill-Murray RC, Drake KK, Nussear KE, Esque TC et al. (2021) Assessment of disease risk associated with potential removal of anthropogenic barriers to Mojave desert tortoise (*Gopherus agassizii*) population connectivity. *J Wildl Dis* 57: 579–589. <https://doi.org/10.7589/JWD-D-20-00140>.
- Bush ER, Baker SE, Macdonald DW (2014) Global trade in exotic pets 2006–2012. *Conserv Biol* 28: 663–676. <https://doi.org/10.1111/cobi.12240>.
- Castle MD, Christensen BM (1990) Hematozoa of wild turkeys from the midwestern United States: translocation of wild turkeys and its potential role in the introduction of *Plasmodium kempii*. *J Wildl Dis* 26: 180–185. <https://doi.org/10.7589/0090-3558-26.2.180>.
- Charles-Smith LE, Lewbart GA, Aresco MJ, Cowen P (2009) Detection of Salmonella in gopher tortoises (*Gopherus polyphemus*) during two relocation efforts in Florida. *Chelonian Conserv Biol* 8: 213–216. <https://doi.org/10.2744/CCB-0771.1>.
- Christopher MM, Berry KH, Henen BT, Nagy KA (2003) Clinical disease and laboratory abnormalities in free-ranging desert tortoises in California (1990–1995). *J Wildl Dis* 39: 35–56. <https://doi.org/10.7589/0090-3558-39.1.35>.
- Clark EE, Tsaliagos RN, Pittman AB (2001) *Gopherus polyphemus* (gopher tortoise). *Herpetol Rev* 54: 671–679. <https://doi.org/10.7589/2017-09-216>.
- Cohen BS, Belser EH, Keeler SP, Yabsley MJ, Miller KV (2018) A headache from our past? Intracranial abscess disease, virulence factors of trueperella pyogenes, and a legacy of translocating white-tailed deer (*Odocoileus virginianus*). *J Wildl Dis* 54: 671–679. <https://doi.org/10.7589/2017-09-216>.
- Cozad RA (2018) Investigation of health in translocated gopher tortoises (*Gopherus polyphemus*) at a protected site in northwest Florida. M.S. thesis. University of Georgia, Athens, GA.
- Cozad RA, Hernandez SM, Norton TM, Tuberville TD, Stacy NI, Stedman NL, Aresco MJ (2020a) Epidemiological investigation of a mortality event in a translocated gopher tortoise (*Gopherus polyphemus*) population in northwest Florida. *Front Vet Sci* 7. <https://doi.org/10.3389/fvets.2020.00120>.
- Cozad RA, Norton TM, Aresco MJ, Allender MC, Hernandez SM (2020b) Pathogen surveillance and detection of ranavirus (frog virus 3) in translocated gopher tortoises (*Gopherus polyphemus*). *J Wildl Dis* 56: 679–683. <https://doi.org/10.7589/2019-02-053>.
- Crosby FL, Wellehan JFX, Pertierra L, Wendland LD, Lundgren AM, Barbet AF, Brown MB (2021) Molecular characterization of *Candidatus Anaplasma testudinis*: an emerging pathogen in the threatened Florida gopher tortoise (*Gopherus polyphemus*). *Ticks Tick Borne Dis* 12: 101672. <https://doi.org/10.1016/j.ttbdis.2021.101672>.
- Daly JA, Buhlmann KA, Todd BD, Moore CT, Peadar JM, Tuberville TD (2018) Comparing growth and body condition of indoor-reared, outdoor-reared, and direct-released juvenile Mojave desert tortoises. *Herpetol Conserv Biol* 13: 622–633.
- Daszak P, Cunningham AA, Hyatt AD (2000) Emerging infectious diseases of wildlife—threats to biodiversity and human health. *Science* 287: 443–449. <https://doi.org/10.1126/science.287.5452.443>.
- Davidson WR, Doster GL, Freeman RC (1996) *Parelaphostrongylus tenuis* on Wassaw Island, Georgia: a result of translocating white-tailed deer. *J Wildl Dis* 32: 701–703. <https://doi.org/10.7589/0090-3558-32.4.701>.
- Davis AK, Maney DL, Maerz JC (2008) The use of leukocyte profiles to measure stress in vertebrates: a review for ecologists. *Funct Ecol* 22: 760–772. <https://doi.org/10.1111/j.1365-2435.2008.01467.x>.
- De Voe R, Geissler K, Elmore S, Rotstein D, Lewbart G, Guy J (2004) Ranavirus-associated morbidity and mortality in a group of captive eastern box turtles (*Terrapene carolina carolina*). *J Zoo Wildl Med* 35: 534–543. <https://doi.org/10.1638/03-037>.
- Deem SL, Karesh WB, Weisman W (2001) Putting theory into practice: wildlife health in conservation. *Conserv Biol* 15: 1224–1233. <https://doi.org/10.1046/j.1523-1739.2001.00336.x>.

- DeGregorio BA, Sperry JH, Tuberville TD, Weatherhead PJ, DeGregorio BA, Sperry JH, Tuberville TD, Weatherhead PJ (2017) Translocating ratsnakes: does enrichment offset negative effects of time in captivity? *Wildl Res* 44: 438–448. <https://doi.org/10.1071/WR17016>.
- DeGregorio BA, Weatherhead PJ, Tuberville TD, Sperry JH (2013) Time in captivity affects foraging behavior of ratsnakes: implications for translocation. *Herpetol Conserv Biol* 8: 581–590.
- Desiderio TM, Stacy NI, Ossiboff RJ, Iredale M, Archer LL, Alexander AB, Heard DJ, Crevasse SE, Craft WF, Fredholm DVE *et al.* (2021) Identification of a novel mortality-associated *Helicobacter* species in gopher tortoises (*Gopherus polyphemus*), qPCR test development and validation, and correlation with mortality in a wildlife rehabilitation population. *Vet Microbiol* 259: 109136. <https://doi.org/10.1016/j.vetmic.2021.109136>.
- Diaz-Figueroa O (2005) Characterizing the health status of the Louisiana gopher tortoise (*Gopherus polyphemus*). M.S. thesis. Louisiana State University, Baton Rouge, Louisiana.
- Dickens MJ, Delehanty DJ, Michael Romero L (2010) Stress: an inevitable component of animal translocation. *Biol Conserv* 143: 1329–1341. <https://doi.org/10.1016/j.biocon.2010.02.032>.
- Diemer JE (1986) The ecology and management of the gopher tortoise in the southeastern United States. *Herpetologica* 46: 695–705. <https://doi.org/10.7589/0090-3558-46.3.695>.
- Drake KK, Aiello CM, Bowen L, Lewison RL, Esque TC, Nussear KE, Waters SC, Hudson PJ (2019) Complex immune responses and molecular reactions to pathogens and disease in a desert reptile (*Gopherus agassizii*). *Ecol Evol* 9: 2516–2534. <https://doi.org/10.1002/ece3.4897>.
- Elbers JP, Taylor SS (2019) *Mycoplasma* prevalence in a reintroduced gopher tortoise (*Gopherus polyphemus*) population. *Herpetol Conserv Biol* 14: 568–577.
- Feldman SH, Wimsatt J, Marchang RE, Johnson AJ, Brown W, Mitchell JC, Sleeman JM (2006) A novel mycoplasma detected in association with upper respiratory disease syndrome in free-ranging eastern box turtles (*Terrapene carolina carolina*) in Virginia. *J Wildl Dis* 42: 279–289. <https://doi.org/10.7589/0090-3558-42.2.279>.
- Fischer J, Lindenmayer DB (2000) An assessment of the published results of animal relocations. *Biol Conserv* 96: 1–11. [https://doi.org/10.1016/S0006-3207\(00\)00048-3](https://doi.org/10.1016/S0006-3207(00)00048-3).
- Fitzgerald LA, Treglia ML, Angeli N, Hibbitts TJ, Leavitt DJ, Subalusky AL, Lundgren I, Hillis-Starr Z (2015) Determinants of successful establishment and post-translocation dispersal of a new population of the critically endangered St. Croix ground lizard (*Ameiva polops*). *Restor Ecol* 23: 776–786. <https://doi.org/https://doi.org/10.1111/rec.12248>.
- Florida Fish and Wildlife Conservation Commission (2006) *Available options to address the presence of gopher tortoises on lands slated for development*. Retrieved from: http://www.jeffersoncountyfl.gov/Uploads/Editor/file/planning/tortoise_relocation_guidelines.pdf.
- Florida Fish and Wildlife Conservation Commission (2012) Gopher tortoise management plan. Retrieved from: <https://www.nbbd.com/gophertortoise/1209-ManagementPlan.pdf>.
- Gates CA, Allen MJ, Berish JED, Stillwaugh DM, Shattler SR (2002) Characterization of a gopher tortoise mortality event in west-central Florida. *Florida Scientist* 65: 185–197.
- Germano JM, Bishop PJ (2009) Suitability of amphibians and reptiles for translocation. *Conserv Biol* 23: 7–15. <https://doi.org/10.1111/j.1523-1739.2008.01123.x>.
- Gibbons JW, Scott DE, Ryan TJ, Buhlmann KA, Tuberville TD, Metts BS, Greene JL, Mills T, Leiden Y, Poppy S *et al.* (2000) The global decline of reptiles, déjà vu amphibians: reptile species are declining on a global scale. Six significant threats to reptile populations are habitat loss and degradation, introduced invasive species, environmental pollution, disease, unsustainable use, and global climate change. *Bioscience* 50: 653–666. [https://doi.org/10.1641/0006-3568\(2000\)050\[0653:TGDORD\]](https://doi.org/10.1641/0006-3568(2000)050[0653:TGDORD]).
- Goessling JM, Guyer C, Godwin JC, Hermann SM, Sandmeier FC, Smith LL, Mendonça MT (2019) Upper respiratory tract disease and associated diagnostic tests of mycoplasmosis in Alabama populations of gopher tortoises, *Gopherus polyphemus*. *PLoS One* 14: e0214845. <https://doi.org/10.1371/journal.pone.0214845>.
- Goessling JM, Guyer C, Mendonça MT (2016) Seasonal acclimation of constitutive immunity in gopher tortoises *Gopherus polyphemus*. *Physiol Biochem Zool* 89: 487–497. <https://doi.org/10.1086/688694>.
- Goessling JM, Mendonça MT (2021) Physiological responses of gopher tortoises (*Gopherus polyphemus*) to trapping. *Conserv Physiol* 9: coab003. <https://doi.org/10.1093/conphys/coab003>.
- Golovchenko M, Sima R, Hajdusek O, Grubhoffer L, Oliver JH, Rudenko N (2014) Invasive potential of *Borrelia burgdorferi* sensu stricto ospC type L strains increases the possible disease risk to humans in the regions of their distribution. *Parasit Vectors* 7: 538. <https://doi.org/10.1186/s13071-014-0538-y>.
- Gopher Tortoise Council (2014) Gopher tortoise minimum viable population and minimum reserve size working group report II. Retrieved from http://gophertortoiseCouncil.org/pdf/MVP_II_2014_GTC_report_group_final.pdf
- Gregory LF, Gross TS, Bolten AB, Bjorndal KA, Guillette Jr Louis J (1996) Plasma corticosterone concentrations associated with acute captivity stress in wild loggerhead sea turtles (*Caretta caretta*). *Gen and Comp Endocrinol* 104: 312–320. <https://doi.org/10.1006/gcen.1996.0176>.
- Gupta RS, Sawhani S, Adeolu M, Alnajjar S, Oren A (2018) Phylogenetic framework for the phylum Tenericutes based on genome sequence data: proposal for the creation of a new order Mycoplasmoidales ord. nov., containing two new families Mycoplasmoidaceae fam. nov. and Metamycoplasmataceae fam. nov. harbouring Eperythrozoon, Ureaplasma and five novel genera. *Antonie Van Leeuwenhoek* 111: 1583–1630. <https://doi.org/10.1007/s10482-018-1047-3>.
- Hartup BK, Kollias GV, Jacobsen MC, Valentine BA, Kimber KR (1999) Exertional myopathy in translocated river otters from New York. *J Wildl Dis* 35: 542–547. <https://doi.org/10.7589/0090-3558-35.3.542>.
- Holbrook AL (2015) Maternal effects and offspring behavior: potential contributors to the lack of recruitment in Mississippi gopher tortoises

- (*Gopherus polyphemus*). M.S. thesis. University of Southern Mississippi, Hattiesburg, Mississippi.
- Hurvich CM, Tsai C-L (1989) Regression and time series model selection in small samples. *Biometrika* 76: 297–307. <https://doi.org/10.1093/biomet/76.2.297>.
- Jacobson ER, Gaskin JM, Brown MB, Harris RK, Gardiner CH, LaPointe JL, Adams HP, Reggiardo C (1991a) Causes of mortality and diseases in tortoises: a review. *J Zoo Wildl Med* 27: 296–316. <https://doi.org/10.7589/0090-3558-27.2.296>.
- Jacobson ER, Brown MB, Wendland LD, Brown DR, Klein PA, Christopher MM, Berry KH (2014) Mycoplasmosis and upper respiratory tract disease of tortoises: a review and update. *Vet J* 201: 257–264. <https://doi.org/10.1016/j.tvjl.2014.05.039>.
- Jacobson ER, Gaskin JM, Brown MB, Harris RK, Gardiner CH, LaPointe JL, Adams HP, Reggiardo C (1991b) Chronic upper respiratory tract disease of free-ranging desert tortoises (*Xerobates agassizii*). *J Wildl Dis* 27: 296–316. <https://doi.org/10.7589/0090-3558-27.2.296>.
- Jarvie S, Recio MR, Adolph SC, Seddon PJ, Cree A (2016) Resource selection by tuatara following translocation: a comparison of wild-caught and captive-reared juveniles. *N Z J Ecol* 40: 334–341. <https://doi.org/10.20417/nzjecol.40.35>.
- Johnson AJ, Morafka DJ, Jacobson ER (2006) Seroprevalence of *Mycoplasma agassizii* and tortoise herpesvirus in captive desert tortoises (*Gopherus agassizii*) from the Greater Barstow Area, Mojave Desert, California. *J Arid Environ* 67: 192–201. <https://doi.org/10.1016/j.jaridenv.2006.09.025>.
- Johnson AJ, Pessier AP, Wellehan JFX, Childress A, Norton TM, Stedman NL, Bloom DC, Belzer W, Titus VR, Wagner R *et al.* (2008) Ranavirus infection of free-ranging and captive box turtles and tortoises in the United States. *J Wildl Dis* 44: 851–863. <https://doi.org/10.7589/0090-3558-44.4.851>.
- Johnson WE, Onorato DP, Roelke ME, Land ED, Cunningham M, Belden RC, Mc Bride R, Jansen D, Lotz M, Shindle D *et al.* (2010) Genetic restoration of the Florida panther. *Science* 329: 1641–1645. <https://doi.org/10.1126/science.1192891>.
- Juul-Madsen HR, Viertlböck B, Härtle S, Smith AL, Göbel TW (2014) Chapter 7: innate immune responses. In Schat KA, Kaspers B, Kaiser P, eds, *Avian Immunology*, Ed 2. Elsevier, Boston, pp. 121–147. [10.1016/B978-0-12-396965-1.00007-8](https://doi.org/10.1016/B978-0-12-396965-1.00007-8).
- Karlin ML (2008) Distribution of *Mycoplasma agassizii* in a gopher tortoise population in south Florida. *Southeast Nat* 7: 145–158. [https://doi.org/10.1656/1528-7092\(2008\)7\[145:DOMAIA\]2.0.CO;2](https://doi.org/10.1656/1528-7092(2008)7[145:DOMAIA]2.0.CO;2).
- Kock RA, Woodford MH, Rossiter PB (2010) Disease risks associated with the translocation of wildlife. *Rev Sci Tech* 29: 329–350. <https://doi.org/10.20506/rst.29.2.1980>.
- Kraus BT, McCallen EB, Williams RN (2017) Evaluating the survival of translocated adult and captive-reared, juvenile eastern hellbenders (*Cryptobranchus alleganiensis alleganiensis*). *Herpetologica* 73: 271–276. <https://doi.org/10.1655/Herpetologica-D-16-00009>.
- Levin RE (2009) The use of molecular methods for detecting and discriminating salmonella associated with foods—a review. *Food Biotechnol* 23: 313–367. <https://doi.org/10.1080/08905430903320982>.
- Lockhart JM, Lee G, Turco J, Chamberlin L (2008) Salmonella from gopher tortoises (*Gopherus polyphemus*) in south Georgia. *J Wildl Dis* 44: 988–991. <https://doi.org/10.7589/0090-3558-44.4.988>.
- Loehr VJT, Henen BT, Hofmeyr MD (2004) Reproduction of the smallest tortoise, the Namaqualand speckled padloper, *Homopus signatus signatus*. *Herpetologica* 60: 444–454. <https://doi.org/10.1655/03-59>.
- Mason GJ (2010) Species differences in responses to captivity: stress, welfare and the comparative method. *Trends Ecol Evol* 25: 713–721. <https://doi.org/10.1016/j.tree.2010.08.011>.
- McCoy ED, Mushinsky HR, Lindzey J (2007) Conservation strategies and emergent diseases: the case of upper respiratory tract disease in the gopher tortoise. *Chelonian Conserv Biol* 6: 170–176. [https://doi.org/10.2744/1071-8443\(2007\)6\[170:CSAEDT\]2.0.CO;2](https://doi.org/10.2744/1071-8443(2007)6[170:CSAEDT]2.0.CO;2).
- McGuire JL, Smith LL, Guyer C, Lockhart JM, Lee GW, Yabsley MJ (2014) Surveillance for upper respiratory tract disease and mycoplasma in free-ranging gopher tortoises (*Gopherus polyphemus*) in Georgia, USA. *J Wildl Dis* 50: 733–744. <https://doi.org/10.7589/2013-11-300>.
- McKee RK, Buhlmann KA, Moore CT, Hepinstall-Cymerman J, Tuberville TD (2021) Waif gopher tortoise survival and site fidelity following translocation. *J Fish Wildl Manag* 85: 640–653. <https://doi.org/10.1002/jwmg.21998>.
- McKee RM (2019) An island of misfit tortoises: evaluating the use of waif animals to recover populations on the brink. M.S. thesis. University of Georgia, Athens, GA.
- McLaughlin GS (1997) Upper respiratory tract disease in gopher tortoises, *Gopherus polyphemus*: pathology, immune responses, transmission, and implications for conservation and management. Ph.D. thesis. University of Florida, Gainesville, FL.
- McLaughlin GS, Jacobson ER, Brown DR, McKenna CE, Schumacher IM, Adams HP, Brown MB, Klein PA (2000) Pathology of upper respiratory tract disease of gopher tortoises in Florida. *J Wildl Dis* 36: 272–283. <https://doi.org/10.7589/0090-3558-36.2.272>.
- Mendiratta U, Sheel V, Singh S (2017) Enforcement seizures reveal large-scale illegal trade in India's tortoises and freshwater turtles. *Biol Conserv* 207: 100–105. <https://doi.org/10.1016/j.biocon.2017.01.023>.
- Neuman-Lee LA, Van Wettere AJ, French SS (2019) Interrelations among multiple metrics of immune and physiological function in a squamate, the common gartersnake (*Thamnophis sirtalis*). *Physiol Biochem Zool* 92: 12–23. <https://doi.org/10.1086/700396>.
- Ohmer MEB, Costantini D, Cziráj GÁ, Downs CJ, Ferguson LV, Flies A, Franklin CE, Kayigwe AN, Knutie S, Richards-Zawacki CL *et al.* (2021) Applied ecoimmunology: using immunology tools to improve conservation efforts in a changing world. *Conserv Physiol* 9: coab074. <https://doi.org/10.1093/conphys/coab074>.

- Origi FC, Jacobson ER (2000) Diseases of the respiratory tract of chelonians. *Vet Clin North Am Exot Anim Pract* 3: 537–549. [https://doi.org/10.1016/S1094-9194\(17\)30088-9](https://doi.org/10.1016/S1094-9194(17)30088-9).
- Ossiboff RJ, Raphael BL, Ammazalorso AD, Seimon TA, Niederriter H, Zarate B, Newton AL, McAloose D (2015) A mycoplasma species of Emydidae turtles in the northeastern USA. *J Wildl Dis* 51: 466–470. <https://doi.org/10.7589/2014-04-086>.
- Ozgul A, Oli MK, Bolker BM, Perez-Heydrich C (2009) Upper respiratory tract disease, force of infection, and effects on survival of gopher tortoises. *Ecol Appl* 19: 786–798. <https://doi.org/10.1890/08-0219.1>.
- Page-Karjian A, Rafferty K, Xavier C, Stacy NI, Moore JA, Hirsch SE, Clark S, Manire CA, Perrault JR (2021) Comprehensive health assessment and blood analyte reference intervals of gopher tortoises (*Gopherus polyphemus*) in southeastern FL, USA. *Conserv Physiol* 9. <https://doi.org/10.1093/conphys/coab015>.
- Pallister J, Gould A, Harrison D, Hyatt A, Jancovich J, Heine H (2007) Development of real-time PCR assays for the detection and differentiation of Australian and European ranaviruses. *J Fish Dis* 30: 427–438. <https://doi.org/10.1111/j.1365-2761.2007.00828.x>.
- Park H-J, Kim H-J, Park S-H, Shin E-G, Kim J-H, Kim H-Y (2008) Direct and quantitative analysis of salmonella enterica serovar typhimurium using real-time PCR from artificially contaminated chicken meat. *J Microbiol Biotechnol* 18: 1453–1458.
- Perez K, Mullen N, Canter JA, Ley DH, May M (2020) Phenotypic diversity in an emerging mycoplasmal disease. *Microb Pathog* 138: 103798. <https://doi.org/10.1016/j.micpath.2019.103798>.
- Pessier AP (2008) Management of disease as a threat to amphibian conservation. *Int Zoo Yearb* 42: 30–39. <https://doi.org/10.1111/j.1748-1090.2008.00047.x>.
- R Core Team (2020) R: a language and environment for statistical computing Version 4.0.2. R Foundation for Statistical Computing, Vienna, Austria.
- Rosen GE, Smith KF (2010) Summarizing the evidence on the international trade in illegal wildlife. *Ecohealth* 7: 24–32. <https://doi.org/10.1007/s10393-010-0317-y>.
- Rosenberg JF, Hernandez JA, Wellehan JFX, Crevasse SE, Cray C, Stacy NI (2018a) Diagnostic performance of inflammatory markers in gopher tortoises (*Gopherus polyphemus*). *J Zoo Wildl Med* 49: 765–769. <https://doi.org/10.1638/2017-0211.1>.
- Rosenberg JF, Wellehan James FX, Crevasse SE, Cray C, Stacy NI (2018b) Reference intervals for erythrocyte sedimentation rate, lactate, fibrinogen, hematology, and plasma protein electrophoresis in clinically healthy captive gopher tortoises (*Gopherus polyphemus*). *J Zoo Wildl Med* 49: 520–527. <https://doi.org/10.1638/2017-0183.1>.
- Sandmeier FC, Leonard KL, Tracy CR, Drake KK, Esque TE, Nussear K, Germano JM (2019a) Tools to understand seasonality in health: quantification of microbe loads and analyses of compositional ecoimmunological data reveal complex patterns in Mojave Desert tortoise (*Gopherus agassizii*) populations. *Can J Zool* 97: 841–848. <https://doi.org/10.1139/cjz-2018-0255>.
- Sandmeier FC, Maloney KN, Tracy CR, Hyde D, Mohammadpour H, Marlow R, DuPré S, Hunter K (2017) Chronic disease in the Mojave desert tortoise: host physiology and recrudescence obscure patterns of pathogen transmission. *Ecol Evol* 7: 10616–10629. <https://doi.org/10.1002/ece3.3480>.
- Sandmeier FC, Ruiz R, Leonard K, Bayer B, Dowd C, Urban T (2019b) A quantitative PCR assay for a mycoplasma from emydid turtles indicates high prevalence in healthy three-toed box turtles (*Terrapene carolina triunguis*) from Missouri, USA. *J Wildl Dis* 55: 589–596. <https://doi.org/10.7589/2018-09-221>.
- Sandmeier FC, Tracy CR, duPré S, Hunter K (2009) Upper respiratory tract disease (URTD) as a threat to desert tortoise populations: a reevaluation. *Biol Conserv* 142: 1255–1268. <https://doi.org/10.1016/j.biocon.2009.02.001>.
- Sandmeier FC, Weitzman CL, Tracy CR (2018) An ecoimmunological approach to disease in tortoises reveals the importance of lymphocytes. *Ecosphere* 9: e02427. <https://doi.org/10.1002/ecs2.2427>.
- Schaffer GD, Davidson WR, Nettles VF, Rollor EA (1981) Helminth parasites of translocated raccoons (*Procyon lotor*) in the southeastern United States. *J Wildl Dis* 17: 217–227. <https://doi.org/10.7589/0090-3558-17.2.217>.
- Schumacher IM, Brown MB, Jacobson ER, Collins BR, Klein PA (1993) Detection of antibodies to a pathogenic mycoplasma in desert tortoises (*Gopherus agassizii*) with upper respiratory tract disease. *J Clin Microbiol* 31: 1454–1460. <https://doi.org/10.1128/JCM.31.6.1454-1460.1993>.
- Schumacher IM, Hardenbrook DB, Brown MB, Jacobson ER, Klein PA (1997) Relationship between clinical signs of upper respiratory tract disease and antibodies to *Mycoplasma agassizii* in desert tortoises from Nevada. *J Wildl Dis* 33: 261–266. <https://doi.org/10.7589/0090-3558-33.2.261>.
- Seigel RA, Smith RB, Seigel NA (2003) Swine flu or 1918 pandemic? Upper respiratory tract disease and the sudden mortality of gopher tortoises (*Gopherus polyphemus*) on a protected habitat in Florida. *J Herpetol* 37: 137–144. [https://doi.org/10.1670/0022-1511\(2003\)037\[0137:SFOPUR\]2.0.CO;2](https://doi.org/10.1670/0022-1511(2003)037[0137:SFOPUR]2.0.CO;2).
- Sim RR, Allender MC, Crawford LK, Wack AN, Murphy KJ, Mankowski JL, Bronson E (2016) Ranavirus epizootic in captive eastern box turtles (*Terrapene carolina carolina*) with concurrent herpesvirus and mycoplasma infection: management and monitoring. *J Zoo Wildl Med* 47: 256–270.
- Smith LL, Tuberville TD, Seigel RA (2006) Workshop on the ecology, status, and management of the gopher tortoise (*Gopherus polyphemus*), Joseph W. Jones Ecological Research Center, 16-17 January 2003: final results and recommendations. *Chelonian Conserv Biol* 5: 326–330. [https://doi.org/10.2744/1071-8443\(2006\)5\[326:WOTESAJ\]2.0.CO;2](https://doi.org/10.2744/1071-8443(2006)5[326:WOTESAJ]2.0.CO;2).
- Smith RB, Seigel RA, Smith KR (1998) Occurrence of upper respiratory tract disease in gopher tortoise populations in Florida and Mississippi. *J Herpetol* 32: 426–430. <https://doi.org/10.2307/1565458>.

- Smith RB, Tuberville TD, Chambers AL, Herpich KM, Berish JE (2005) Gopher tortoise burrow surveys: external characteristics, burrow cameras, and truth. *Appl Herpetol* 2: 161–170. <https://doi.org/10.1163/1570754043492081>.
- Stacy NI, Alleman AR, Saylor KA (2011) Diagnostic hematology of reptiles. *Clin Lab Med* 31: 87–108. <https://doi.org/10.1016/j.cll.2010.10.006>.
- Stacy NI, Fredholm DV, Rodriguez C, Castro L, Harvey JW (2017) Whip-like heterophil projections in consecutive blood films from an injured gopher tortoise (*Gopherus polyphemus*) with systemic inflammation. *Vet Q* 37: 162–165. <https://doi.org/10.1080/01652176.2017.1325538>.
- Stacy NI, Hollinger C, Arnold JE, Cray C, Pendl H, Nelson PJ, Harvey JW (2022) Left shift and toxic change in heterophils and neutrophils of non-mammalian vertebrates: a comparative review, image atlas, and practical considerations. *Vet Clin Pathol* 51: 18–44. <https://doi.org/10.1111/vcp.13117>.
- Stanford CB, Iverson JB, Rhodin AGJ, Paul van Dijk P, Mittermeier RA, Kuchling G, Berry KH, Bertolero A, Bjorndal KA, Blanck TEG *et al.* (2020) Turtles and tortoises are in trouble. *Curr Biol* 30: R721–R735. <https://doi.org/10.1016/j.cub.2020.04.088>.
- Stuart SN, Chanson JS, Cox NA, Young BE, Rodrigues ASL, Fischman DL, Waller RW (2004) Status and trends of amphibian declines and extinctions worldwide. *Science* 306: 1783–1786. <https://doi.org/10.1126/science.1103538>.
- Sullivan BK, Nowak EM, Kwiatkowski MA (2015) Problems with mitigation translocation of herpetofauna. *Conserv Biol* 29: 12–18. <https://doi.org/10.1111/cobi.12336>.
- Teixeira CP, de Azevedo CS, Mendl M, Cipreste CF, Young RJ (2007) Revisiting translocation and reintroduction programmes: the importance of considering stress. *Anim Behav* 73: 1–13. <https://doi.org/10.1016/j.anbehav.2006.06.002>.
- Tompkins DM, Carver S, Jones ME, Krkošek M, Skerratt LF (2015) Emerging infectious diseases of wildlife: a critical perspective. *Trends Parasitol* 31: 149–159. <https://doi.org/10.1016/j.pt.2015.01.007>.
- Tuberville TD, Clark EE, Buhlmann KA, Gibbons JW (2005) Translocation as a conservation tool: site fidelity and movement of repatriated gopher tortoises (*Gopherus polyphemus*). *Anim Conserv* 8: 349–358. <https://doi.org/10.1017/S1367943005002398>.
- Tuberville TD, Norton TM, Todd BD, Spratt JS (2008) Long-term apparent survival of translocated gopher tortoises: a comparison of newly released and previously established animals. *Biol Conserv* 141: 2690–2697. <https://doi.org/10.1016/j.biocon.2008.08.004>.
- United States Fish and Wildlife Service (1987) Determination of threatened status for gopher tortoise (*Gopherus polyphemus*). *Fed Regist* 52: 25376–25380.
- United States Fish and Wildlife Service (2011) Endangered and threatened wildlife and plants: 12-month finding on a petition to list the gopher tortoise (*Gopherus polyphemus*) as threatened in the eastern portion of its range. *Fed Regist* 76: 45130–45162.
- Vargas-Hernandez G, André MR, Cendales DM, de Sousa KCM, Gonçalves LR, Rondelli MCH, Machado RZ, Tinucci-Costa M (2016) Molecular detection of *Anaplasma* species in dogs in Colombia. *Rev Bras Parasitol Vet* 25: 459–464. <https://doi.org/10.1590/s1984-296120160066>.
- Walker SF, Bosch J, James TY, Litvintseva AP, Oliver Valls JA, Piña S, García G, Rosa GA, Cunningham AA, Hole S *et al.* (2008) Invasive pathogens threaten species recovery programs. *Curr Biol* 18: R853–R854. <https://doi.org/10.1016/j.cub.2008.07.033>.
- Weiss D (1984) Uniform evaluation and semi-quantitative reporting of hematologic data in veterinary laboratories. *Vet Clin Pathol* 13: 27–31. <https://doi.org/10.1111/j.1939-165X.1984.tb00836.x>.
- Weitzman CL, Sandmeier FC, Tracy CR (2017) Prevalence and diversity of the upper respiratory pathogen *Mycoplasma agassizii* in Mojave Desert tortoises (*Gopherus agassizii*). *Herpetologica* 73: 113–120. <https://doi.org/10.1655/Herpetologica-D-16-00079.1>.
- Wellehan JFX, Johnson AJ, Harrach B, Benkő M, Pessier AP, Johnson CM, Garner MM, Childress A, Jacobson ER (2004) Detection and analysis of six lizard adenoviruses by consensus primer PRC provides further evidence of a reptilian origin for the atadenoviruses. *J Virol* 78: 13366–13369. <https://doi.org/10.1128/JVI.78.23.13366-13369.2004>.
- Wendland LD, Wooding J, White CL, Demcovitz D, Littell R, Berish JD, Ozgul A, Oli MK, Klein PA, Christman MC *et al.* (2010) Social behavior drives the dynamics of respiratory disease in threatened tortoises. *Ecology* 91: 1257–1262. <https://doi.org/10.1890/09-1414.1>.
- Westhouse RA, Jacobson ER, Harris RK, Winter KR, Homer BL (1996) Respiratory and pharyngo-esophageal iridovirus infection in a gopher tortoise (*Gopherus polyphemus*). *J Wildl Dis* 32: 682–686. <https://doi.org/10.7589/0090-3558-32.4.682>.
- Whitfield SM, Ridgley FN, Valle D, Atteberry N (2018) Seroprevalence of *Mycoplasma agassizii* and *Mycoplasma testudineum* in wild and waif gopher tortoises (*Gopherus polyphemus*) in Miami-Dade County, Florida, USA. *Herpetol Rev* 49: 47–49.